To Post or Not- That is the Question

Restorative considerations for a Root Canal Treated Tooth

Praveen Nathaniel
Prosthodontist
Glen Waverley, Moonee Ponds
Melbourne

Would there have been a difference if there was a post?

How do you restore this tooth?

Does this need a post?

Why did this fail and can I retrieve this?

What type of post material should I use?

Pittsburgh dentist admits using paper clips for root canals

Dental board takes no action

"If I felt the need for something that had a little more give, yes, I was taught to use them," Aug 2015

Dentist Who Used Paper Clips Gets Year In Jail

'used sections of paper clips when performing root canals in an effort to save money' Jan 2012

Assess Restorability Of Tooth Prior To Endodontic Treatment

- How much healthy tooth is present
- Is there enough ferrule?
- If not enough, is crown lengthen/ortho extrusion an option?
- Look at perio status, tooth location, adjacent teeth status, parafunctional habits and patient age
- If NOT SUITABLE- bail out NOW and talk about other options

Questionable Prognosis?

Bite the bullet

Look at extraction and other tooth options

Quality of Coronal Seal more important than Endodontic Treatment

- Ray and Tope 1995
- Good RCT/Coronal Restoration 91.4% lack of PA inflammation
- Poor RCT/Coronal restoration 18.1% lack of PA inflammation
- Poor RCT/Good Coronal restoration 67.6% lack of PA inflammation.

Coronal Seal

- After Obturation, seal canal
- Glass Ionomer- Fuji 7, white opaque
- Place Permanent core promptly
- Prepare post space immediately after obturation

Role of Post

- Posts needed to retain core (which retains the crown)
- Connect root portion to core portion

Do Posts Reinforce teeth?

- Weaken teeth or fail to increase fracture resistance
  - Lovdahl 1977
  - Guzy 1979
  - Leary 1987
  - Trope 1985
  - Lu 1987
  - McDonald 1990

Do I Need a Post?

Problems in post preparation

- Weakening of Dentine Walls
- Perforation
- Stripping
- Loss of Apical Seal
- Coronal Microleakage

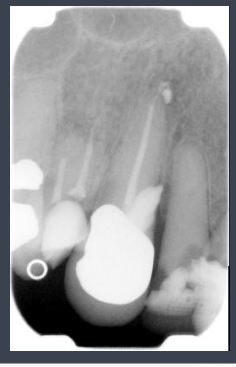

Post or Not Decisions

- Depends on

1) Location in Mouth
2) Ferrule
3) Number of Walls
4) Occlusion
5) Patient factors

Location in Mouth

- Differences in amount of load
- Differences in angle of loading
  - Anteriors- loaded non axially
  - Posteriors mainly vertically

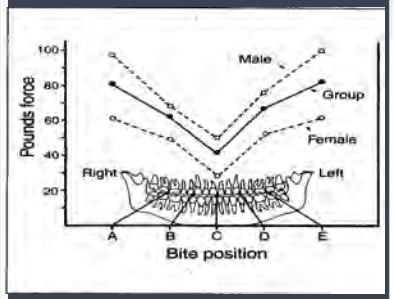

Location in Mouth
Anteriors- Incisors

PROTECTION OF ANTERIOR TEETH?

- Coronal coverage does not significantly improve the success of Anterior RCT.
- Several studies have concluded that remaining tooth structure was more significant for preventing fracture of the tooth and retention of the restoration than was post design or use in anterior teeth.

Guzy 1979, Trope 1985, Sorensen 1984

Anterior teeth

- Small proximal lesions
- Intact cingulum
- Intact incisal ridge
- Intact marginal ridge
- Aesthetically acceptable
- Simple composite


Courtesy Dr Zimet

Anterior Teeth

Undermined marginal ridges

Loss of incisal edge

Coronal fracture

Aesthetically unacceptable

Veneer or Crown

Post and core usually?- assess after crown preparation

Fibre post if unsure

Veneer and Discoloured RCT

Feldspathic Veneer

Anterior Crowns

Anterior Crowns

Location in Mouth
Premolars

Restoration of RCTed Premolars

- Maxillary premolars with MOD restorations had highest failure rates (57% after 10 years)
  Hansen 1990
- MOD composites greater resistance to fracture than amalgams but only for 3 years then the same rate of failures as amalgam
  Hansen 1988

Premolar Teeth

- Look at occlusion
- If poor interdigitation and sufficient tooth structure, restoration may be enough eg lower first premolar

PROTECTION OF PREMOLARS

- Can be subjected to strong lateral forces
- Minimal dentin structure after preparation for PFM crown
- Consider esthetic onlay if sufficient tooth structure remains.
- Post and core if not. Consider crown lengthening for ferrule.

Where to place post in premolars

- Upper first premolars - Palatal canal
- Upper second premolars usually single root- no more than 0.7mm width
- Lowers usually single root
  - no more than 0.9mm diameter

Premolars and post preparation

Watch for possible strip perforation, especially maxillary first premolar

Courtesy Dr Zimet

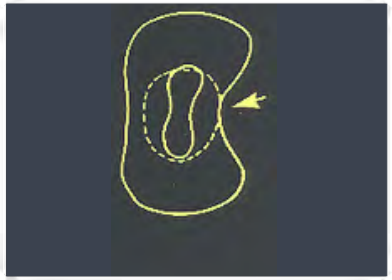

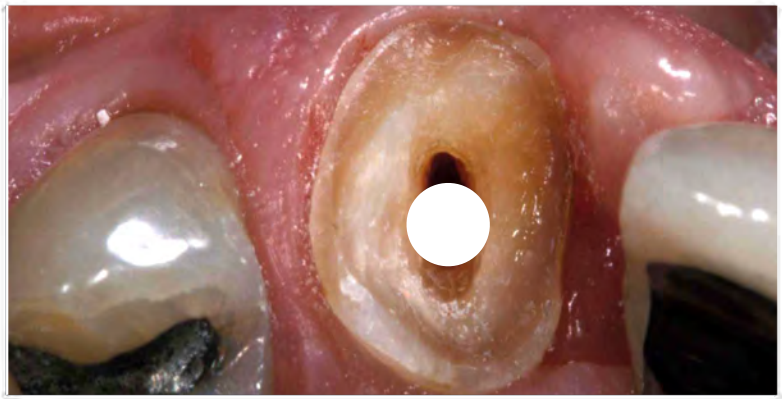

Go with smaller post and use cement to fill gaps or Custom post

Location in Mouth
Posteriors - Molars

PROTECTION OF MOLARS

- Most frequently fractured teeth.
- Cuspal coverage mandatory when in occlusion.
- Generally posts not required.
- If post placed, largest straightest canal
  - Distal lower molar, palatal upper molar
- Ferrule
- Use post if abutment tooth long span bridge (or terminal tooth of free end saddle situation)

Posterior Teeth - Minimal Damage

- Minimal occlusal forces
- Intact Marginal ridges
- Intact cusps
- I'd use composite resin

Nagasari 2005

Posterior Teeth - Moderate Damage

- Missing one marginal ridge
- Cusp coverage amalgam
  - avoid pins
- Porcelain/indirect comp onlay
- Direct Composite as intermediate
- If Crowning with adequate ferrule, core material irrelevant

Pilo 2002

- If using post, no more than 7mm from orifice

Posterior Teeth - Maximal Damage

- No remaining tooth structure
- ?Cast post and core
- Amalgam crown
- Should you even restore?

Osteonecrosis

- RCTed Teeth in Osteonecrosis risk cases
- You may need to restore dubious teeth in teeth cases

Amalgam crowns

Generally suggest these need to be crowned within 5 years

2mm of amalgam overlaid on cusps

Root resection

It has just failed after 15 years

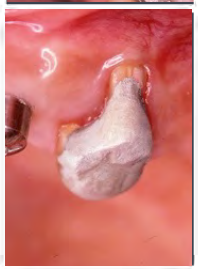

Amalgam Crowns

- Introduced by Nayyar 1980
- Use pulp chamber and amalgam into canals (2-4 mm) especially if pulpal wall height is less than 4mm.
- Amalgapins can be used (Shavell 1986)
- Life-span for complex amalgams can be as long as 11.5 years (Summitt 1987)


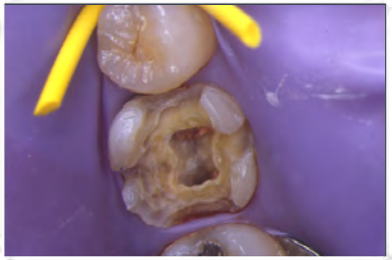

Amalgam crowns

Auxiliary retention- pins (?)/slots/channels
boxes, grooves, undercuts ie use whatever you can!!

Presence of Craze Lines?

Warn Patient

Avoid post placement if possible

Avoid pin placement

Use chamber, slots, keys

Molars, Posts and Bruxers?

Danger Danger Will Robinson



Root fracture

I see these often around 5-7 year mark after post placement



Fractured Root

Courtesy Dr Zimet/post grads

-'ensure your final crown has very flat cusps and no lateral occlusal interferences, to reduce the serious risk of vertical root fracture'

Crown restoration of Molar teeth

Flattened cusps and NO Posts!

What is this Ferrule stuff anyway?

Ferrule Vertical band of tooth at gingival aspect of crown preparation

Schwartz 2004

Ferrule

- Aim for 1-2mm of tooth structure between margin and post/core

  Sorensen 1990, Barkhordar 1989, Eissman 1987, Libman 1995, Mezzomo 2003, N. Al-Hazaimeh 2001

- Not at expense of remaining tooth/root structure

  Stankiewicz 2001

CERVICAL FERRULE

- YES !!!!!
- Increased fracture resistance
- Resistance to dislodgement
- Antirotational
- Stress distribution
- Consider crown lengthening and or extrusion (?subgingival preparation)

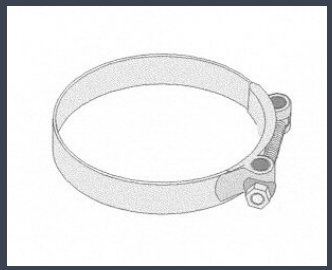

FERRULE EFFECT

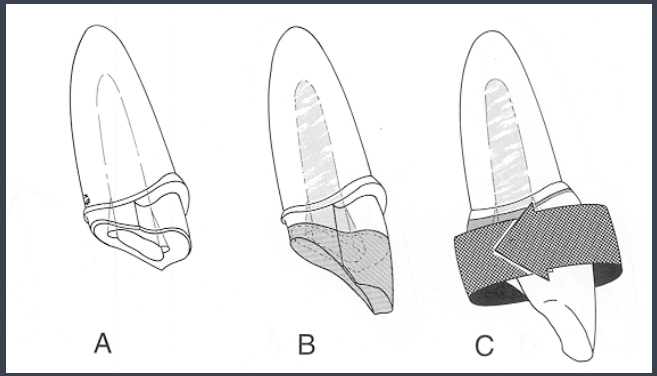

NO FERRULE

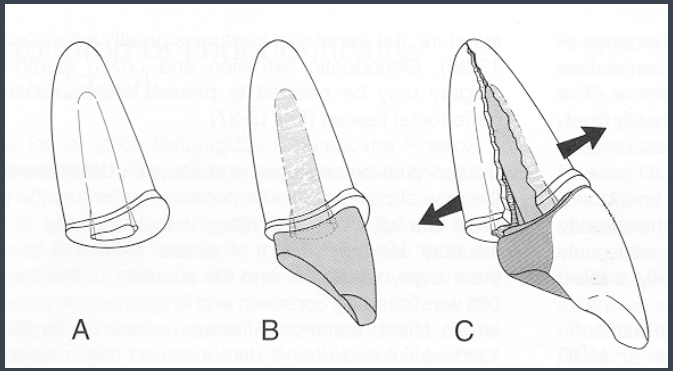

NO FERRULE

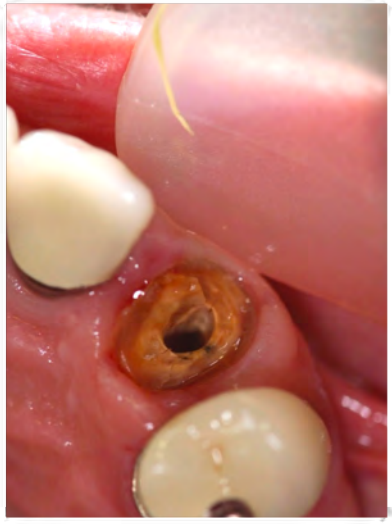

Crown Ferrule

- Crown ferrule is more important than choice between post and core or core construction with adhesive fillings only Bolhuis 2001
- 1-2mm ferrule also reduces vertical fracture by 1/3 and is more likely to be able to retrieved as fractures horizontally (Hoag 1992)

Crown Ferrule

- 3mm ferrule better than 2mm Pereira 2006
- Uniform ferrule gives greater fracture resistance than non-uniform ferrule Tan 2005

Non Uniform Ferrule

- Non uniform ferrule still gives better fracture resistance compared to no ferrule (Tan 2005)
- If palatal structure present on Upper anterior crowns, fracture resistance similar to full ferrule Ng 2006
- Opposite for lower anteriors- i.e. buccal wall important Jotkowitz 2010
- Heights greater than 3mm did not provide significant improvement Al-Wahadni 2002

Ferrule Width is also important

- Need at least 1mm thickness
- Deficiencies in width, height of ferrule as well as canal width
- No wonder restoration failed

How to get additional ferrule

- Crown lengthening
- Orthodontic extrusion
- (Subgingival crown preparation)

Crown lengthening

Our Work Horse

Issues with Crown lengthening

- Removal of bone support for tooth
  - future implant?
- Exposure of furca
- Sensitivity adjacent teeth
- Aesthetic Issues- evenness of gingival line
- Increased Costs
- Pain/Discomfort
- Biomechanical Issues

Orthodontic Extrusion

Don't forget peri cision

Issues with Orthodontic Extrusion

- Additional time
- Additional cost
- Additional procedures- pericision needed
- Aesthetic Issues- Narrowness of root, Braces

Look at number of walls remaining

- To determine whether to place post
- What post to place

Class 1

- 4 walls remaining
- thickness greater than 1mm
- access cavity only
- No post

Class I– III

Two to 4 cavity walls remaining

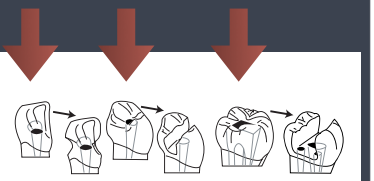

Post
Core
Definitive restoration

No
Adhesive
Any

Peroz 2005

Class 2 and 3

- Three or two walls remaining
- May not need post
- Core with adhesive restoration

Class I– III

Two to 4 cavity walls remaining

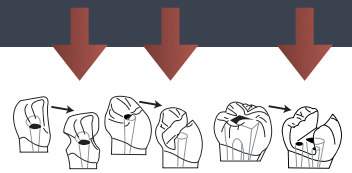

Post
Core
Definitive restoration

No
Adhesive
Any

Peroz 2005

Class 4 - 1 wall remaining

Needs post

Anterior- fibre

Posterior- metal/fibre

Class IV

One cavity wall remaining

Post
Core
Definitive restoration

Fiber
Adhesive
Crown

Fiber/metal
Adhesive/cast
Onlay/crown

Peroz 2005

Class 5

No walls remaining

Needs post

Ferrule important

Class V

No cavity walls remaining

Post
Core
Definitive restoration

Fiber/metal
Adhesive/cast
Crown

Peroz 2005

Also depends as to where the walls are and where the tooth is located

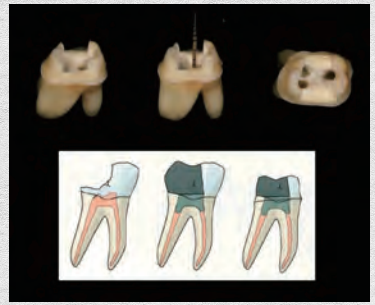

Fig. 12: Two-wall defect with the remaining two walls opposing to each other: amalgam or resin dowel and core is indicated. No post is needed.

Liu 2014 J Pros Impl Dent 3(1):2-16

This time you may consider a post

Fig. 13: Two-wall defect without opposing walls: a prefabricated post cemented in the largest canal can be considered.

Liu 2014 J Pros Impl Dent 3(1):2-16

One wall- post opposite remaining wall

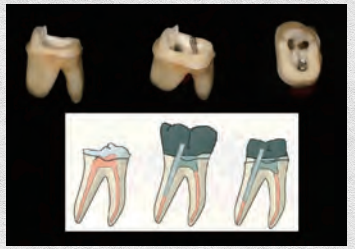

Fig. 14: One-wall defect: A post placement in the canal against the remaining wall.

Liu 2014 J Pros Impl Dent 3(1):2-16

0 Walls - I would go Metal Post/ Cast Post

Fig. 15: 0-wall defect: To assist the retention of core material, a post is placed in the largest palatal canal. For the other two canals, approximately 2-4 mm gutta percha should be removed from the canal orifice.

Ferrule is important
Prognosis is doubtful

Liu 2014 J Pros Impl Dent 3(1):2-16

Occlusion/Patient Factors

- Occlusal scheme- Class 1 vs Class 3
- Guidances- Group function vs Canine rise
- Musculature - Watch with Brachyfacial
- Parafunctional habits - Heavy parafunction
- Cusp heights- High cusps posteriorly give large lateral forces

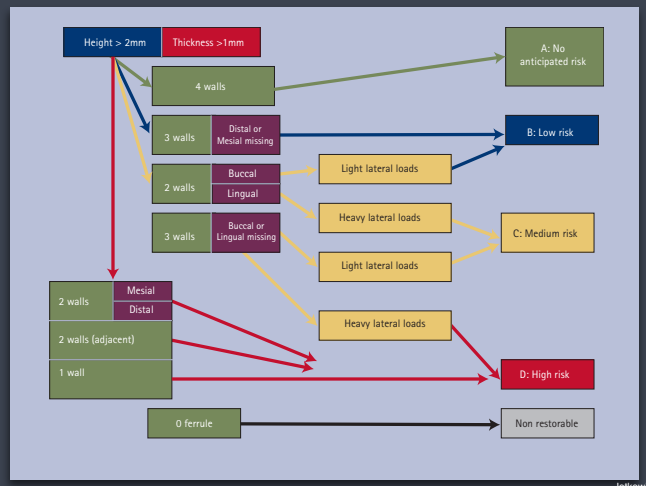

Jotkowitz 2010

If no post used, there needs to be -?

- No horizontal cracks
- No excessive occlusal forces
- Not where excessive guidance required

RCTed teeth and bridges

9 Unit bridge

13 RCTed No post

Fractured core 5 years later

Replaced with implant and cantilever bridge

Preparation of Post space

Use slide cutting burs like Gates gliddens in sequence

Use to length

Use of twist drills with care

Use in hand and with rubber stops

Gives final width

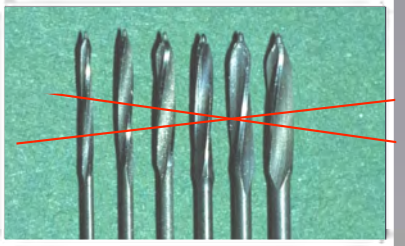

GG/Parapost drill

	Length	Width
Gates Glidden Burs	100%	90%
Parapost Drills	0%	10%

Work in sequence



Ricketts 2005

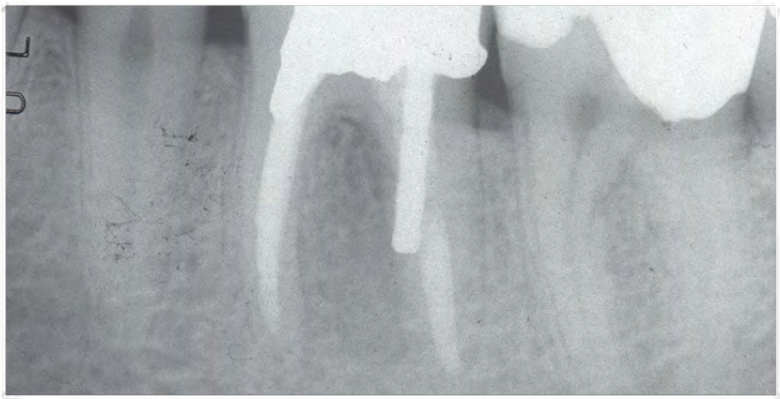

Perforation

Courtesy Dr Zimet

Sometimes people have no idea!

Proposed lengths of posts guidelines

- Equal to crown
- Longer than crown
- 1 and 1/3 times the crown
- 1/2 root length
- 2/3rds root length
- 4/5ths root length
- 1/2 way between the apex and bone
- As long as possible
- 4-5 mm of GP left

Length- Is Bigger Always Better?

Ferrule more important than length (Isidor 1999)

Length of clinical crown

Length of core subgingival

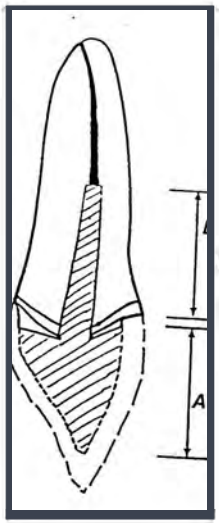

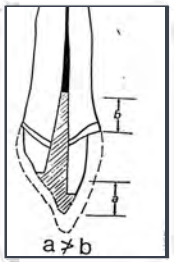

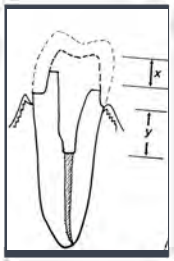

Recommended Configurations for post length

Length of Crown

Greater than length of core intraradicularly

Post needs be below alveolar crest

Periodontally involved teeth

This is where things start getting tricky and there are no hard and fast rules

Extent 4mm apical to bone crest?

GUTTA PERCHA SEAL

Teeth with posts have more apical periodontitis.

Eckerbom et al; Endo Dent Traumatol;1991

Teeth with less than 3mm remaining RCF have significantly more radiolucencies. Kvist et al; J Endo;1989

3mm absolute mininum but preferably 6mm left DeCleen 1993

Do post preparation immediately after RCT Fan 1999

Post Diameter

Increasing width does not increase retention

Standlee 1978

Post diameter should not exceed 1/3 root diameter

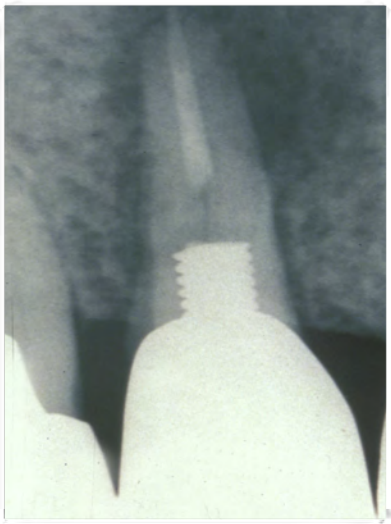

2 piece casting

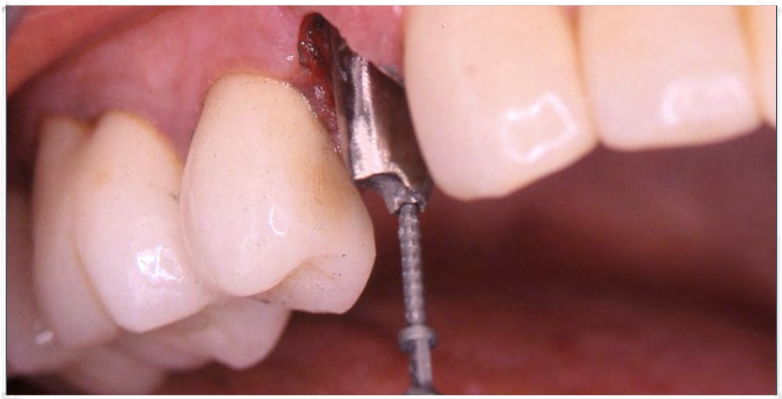

2 piece casting

Types of Posts

- Active vs passive
- Tapered vs straight
- Cast vs Preformed
- Serrated vs Flat
- Metal vs Fibre/Ceramic

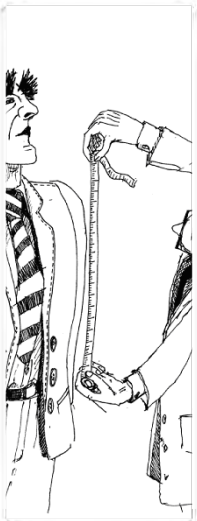

Custom or Prefabricated?

Cast Post and Core

- 'Gold' Standard
- Use for angle correction
- Small teeth
- Minimal tooth structure/root thickness
- Non rounded root canals
- Temporisation issues
- High Au content alloys have lower rate of failure (Balkenhol 2007)

Why would you use each of these Custom cast post materials

- Type 3 Au , Type 4 Au - 'Gold Standard' best accuracy
- Silver-Palladium alloy - ??cost
- Palladium alloy - ??cost
- Base metal alloy - Strength, thin section

Prefabricated posts

- Stainless Steel
  - Strongest of prefab
  - Problems with aesthetics, corrosion
- Parallel Serrated
- Try for 1/3 of post to be in intimate contact

Sorensen 1990

Titanium Prefabricated Posts

- Less rigid than other metal posts
- Can be difficult to detect on radiographs
- Removal issues - Breaks
- Low fracture strength
- Low allergic potential

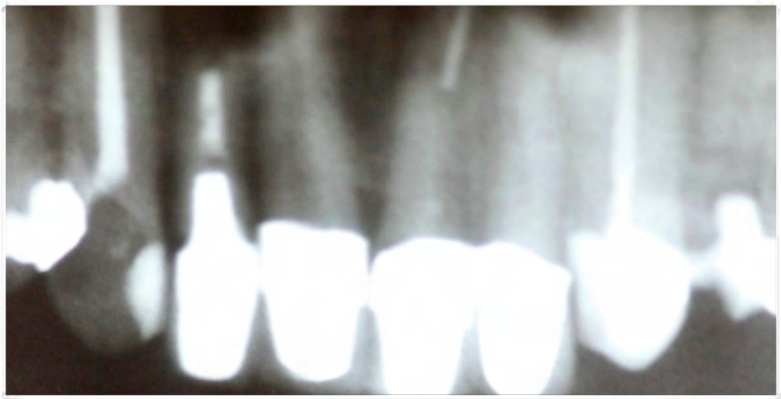

Titanium Post

Anti rotation- Keyways

- May need with prefab posts and circular canals
- Slots or pins
- I prefer slots if needed

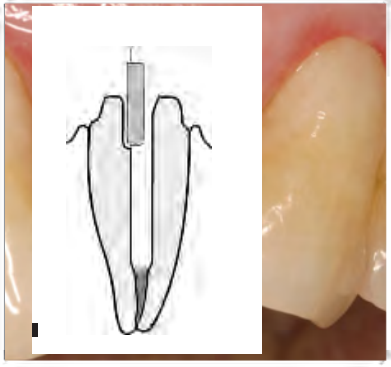

Active or Threaded Posts

- Generally recommend against due to stresses caused in dentine
- Good retention
- Can use if short root with enough root thickness
- If using, unscrew 1/4 turn after installation
- Resin cements give equivalent retention

Aesthetic posts

- Fibre based
- Zirconia

Aesthetics and root canal treated teeth

Aesthetics and root canal treated teeth

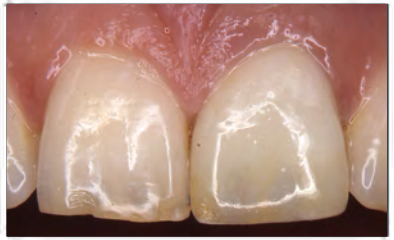

Aesthetics and the discoloured tooth

All ceramic crown

Choose higher opacity core

eg Emax, Procera Aluminia, Zirconia

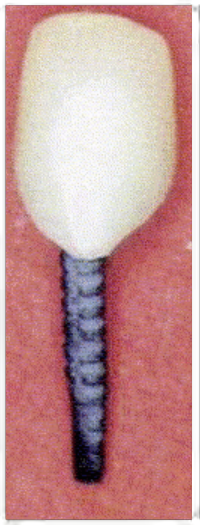

Aesthetics critical?

Don't use SS posts

Polished gold post and core

Use of opaquers/Gold plating
PFM post

Fibre posts

Ceramic posts

Zalkin 1998

WOVEN FIBRE POSTS

- Considerably weaker than other systems
- favourable fractures

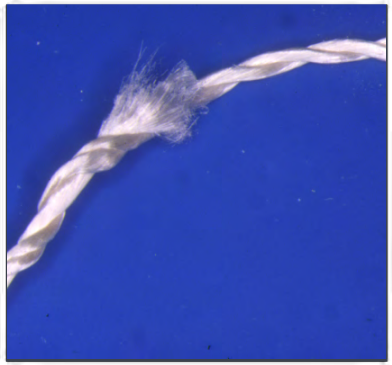

Fibre Posts

- Carbon Fibre
- Quartz Fibre
- Silicon Fibre
- Glass Fibre

Examples
FibreKor
Parapost
Snowpost

Fibre Posts

- White or Clear
- Needs at least 2mm of Ferrule
- Favourable fracture pattern
- Must be bonded in
- No long term history

Akkayan 2004

Same modulus of elasticity as dentine- Good thing?

- Fewer fractures
- However if not supported, movement of core which will lead to microleakage and caries
- Thinner than tooth, should really have greater stiffness (mod of elasticity) to compensate
- ?loss of flexural strength over time

Fibre Posts | Rely X Fibre posts

Parapost Fiber Lux

- Sizes 3 (0.9mm) to 6 (1.5mm)
- Can do indirect as well

Composite Cement is what I usually use

- RelyX Fiber Post
- Elongation Tip
- RelyX Unicem Cement



Cementation is EASY with no need to etch, prime, bond

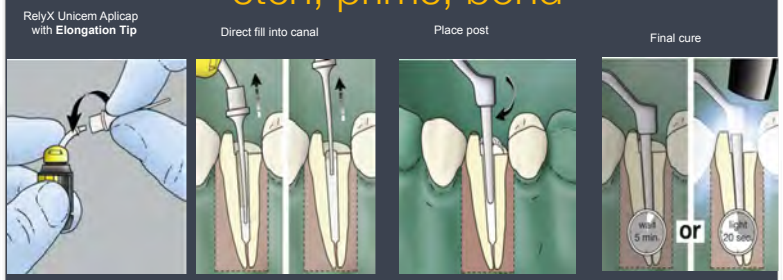

Cementation of Fibre posts

- May need to lightly sandblast or Rocatec/Silacoat to remove highly cross linked polymers to expose glass fibres for silaning or micro mechanical retention. Other authors advise caution, considering sandblasting too aggressive
- Use of phosphoric acid in canal doesn't help
- Use self-etch, self priming cement

Fibre post cementation technique

- Tryin post
- Section with joe dandy, drill
- Decontaminate with alcohol
- Lightly sandblast
- Or
- Immerse in 24% H2O2 for 1 min
- Clean ultrasonic for 5 min then clean with alcohol
- Chlor hex solution 2%
- Miltons irrigation
- Strongly suggest use self etching self priming cement
- Core placement

Atlas Dental learning 1(5):3-20

Cementation Fibre Post

Reliability of Long-term Dentine Bonding

- 28.3 +/- 11.3 MPa (control)
- 15.2 +/- 4.4 MPa (1 to 2 years)
- 9.1 +/- 5.1 MPa (2 to 3 years)

Hashimoto 2000

Plastic Core Materials

- Amalgam
- Composites
- Compomers-Resin reinforced Glass Ionomer
- Glass Ionomers

Does the type of core material matter?

- No effect on survival (17 yr study) (Fokkinga 2007)
- Longevity depends on amount of remaining dentine (Creugers 2005)
- No difference as long as 2mm ferrule is present (Pilo 2002)

Composite Cores

Paraform now being withdrawn from market

?replacement

Paracore/ Paraformer process

Crown design

- Go for flattened cusps
- Avoid Lateral loading
- Share Guidances/ Ease Guidances

Non Crown Restorative Options

- Onlays
  - Porcelain - Emax, Empress
  - Composites- Laboratory fabricated
  - (Au)
- Occlusobuccal veneers
- Shell crowns
- Endo crowns

Onlays

- Use in vertical dimension increase situations
- Where significant amounts of tooth still present but want full coverage
- In compromised molars where after crown preparation, ferrule thickness will be less than 1mm

Empress onlay | now over 20 years old

Thanks for your attention

Any Questions?
praveen@mpcdental.com.au
03- 95611118